

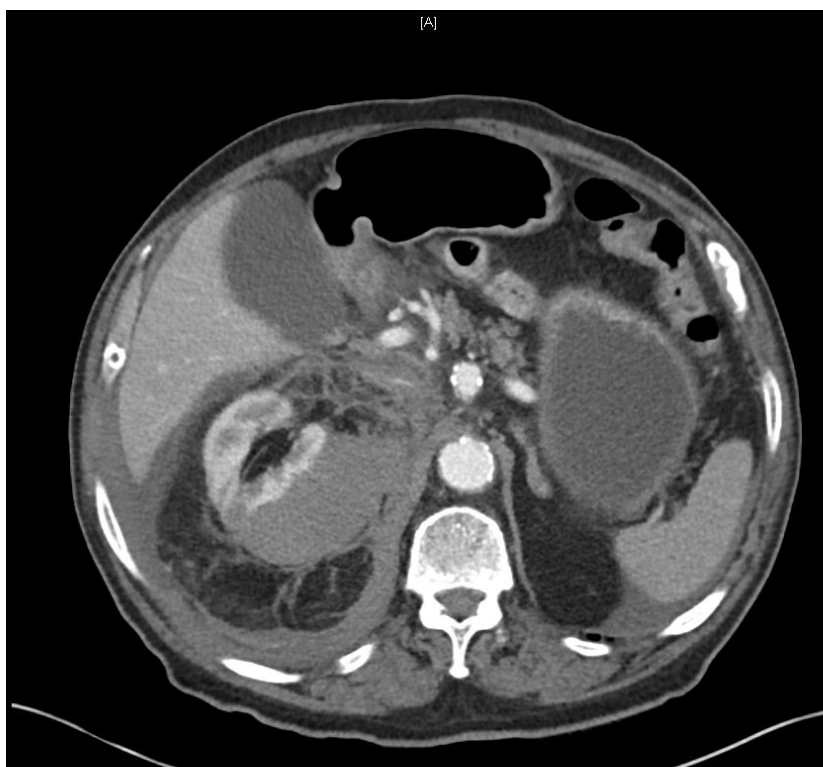
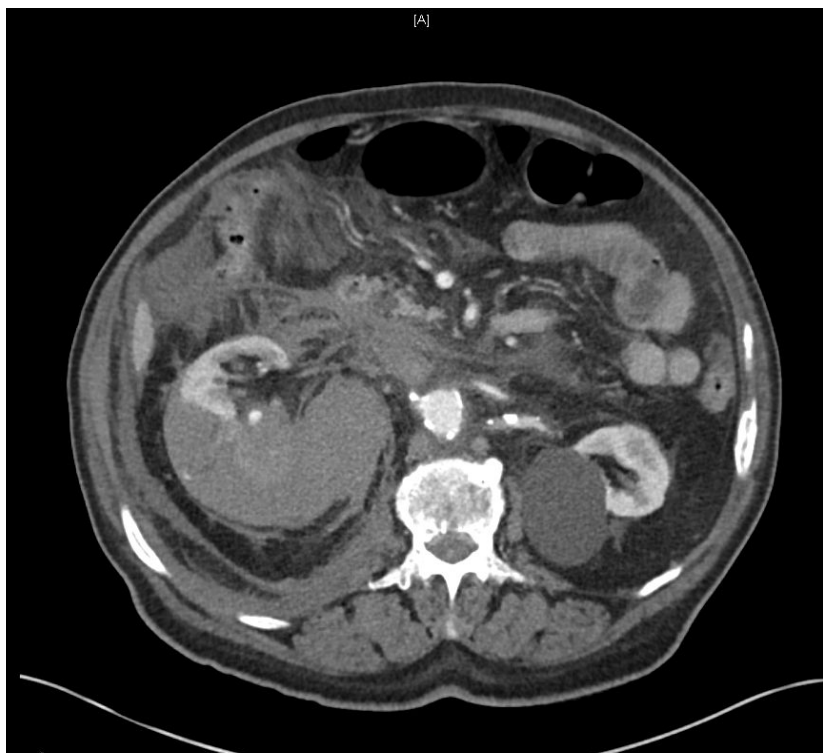## Image of the week March 8

A 75 yo man presents with sudden onset of R flank pain and collapse. He has a past history of atrial fibrillation and hypertension. There is no history of trauma or acute preceding illness.

On initial assessment he is alert, P 88/min, BP 90/50, afebrile

He had marked tenderness in his R flank

He undergoes an radiological imaging – 2 images a reproduced below



1. What type of imaging has been performed? (2 marks)

---

2. Describe 3 POSITIVE and 2 NEGATIVE findings on these images (5 marks)

Positive

a. \_\_\_\_\_

b. \_\_\_\_\_

c. \_\_\_\_\_

Negative

d. \_\_\_\_\_

e. \_\_\_\_\_

3. The patient is on apixiban for atrial fibrillation and took his last dose 1 hour prior to his presentation. He remains hypotensive after 1 litre of crystalloid. Outline 4 steps that you would take to manage his hypotension. Give doses and volumes where relevant (8 marks)

a. \_\_\_\_\_

b. \_\_\_\_\_

c. \_\_\_\_\_

d. \_\_\_\_\_