

In a tertiary ED you receive a Bat Call for a 35 y/o male ETA 10min with penetrating injury to Right Neck.

Vitals GCS 15/15 p 100 BP 108/75 sats 96% air RR 22

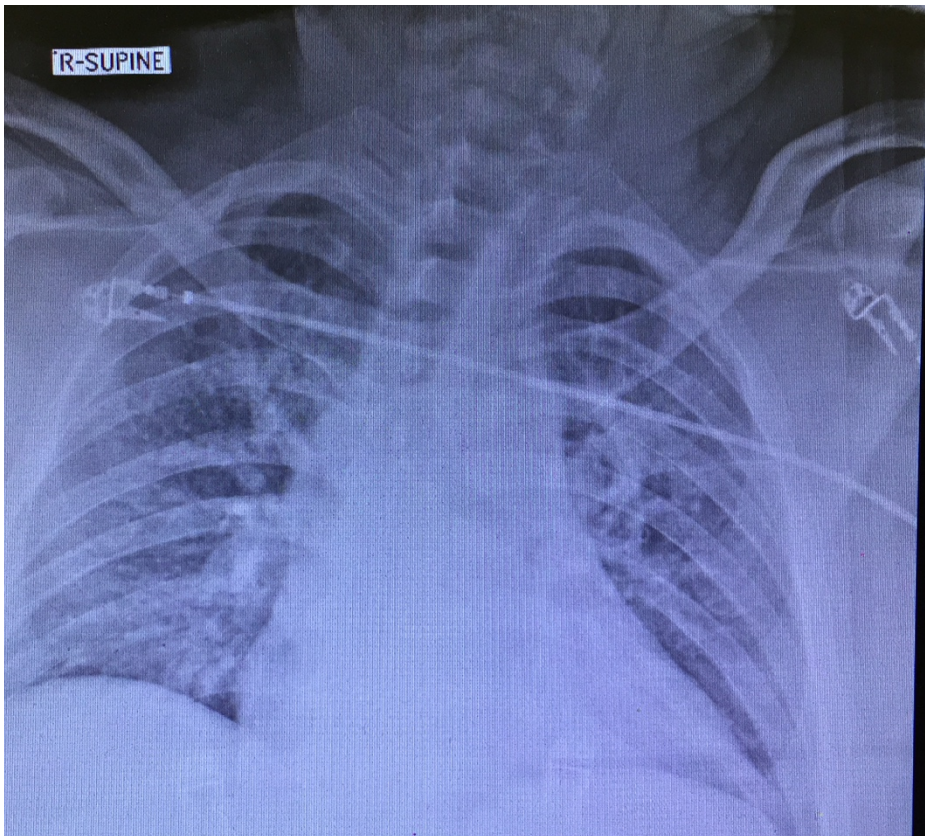
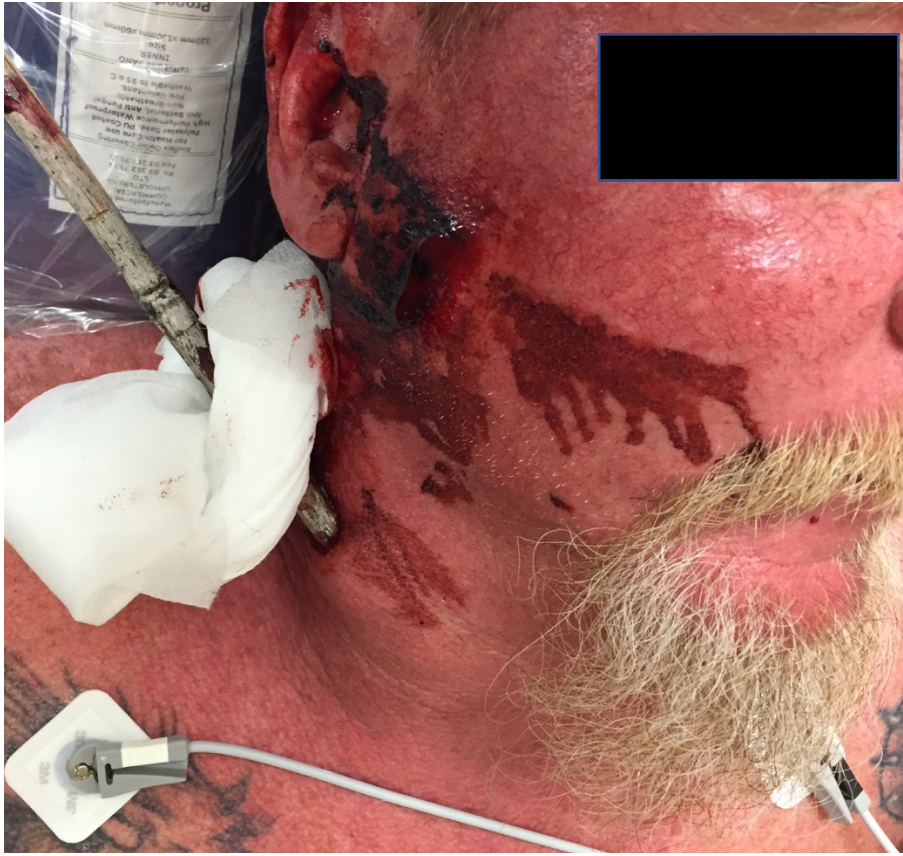Fill out the table below

Zone	Structure Threatened by penetrating injury in this zone	Clinical Sign for injury to this structure
1		
2		
3		

Primary survey reveals isolated penetrating injury to the Right anterior neck superficial to Sternocleidomastoid. He is talking, pain is controlled with 2.5mg morphine IV. Cardiorespiratory exam and Neurological exams are unremarkable.

Outline pros and cons of intubating this patient prior to investigation or operation.

	Intubation prior to OT/lx	No intubation Prior to OT/lx
Pro		
Con		



Give two relevant negative findings on this xray

---

---

What further imaging would you request and why? (2 marks)

---

---

Whilst arranging imaging the radiology registrar notes the patient has a high creatinine and asks for pre-hydration prior to the scan. Outline your response (2 marks).

---

---

---

---