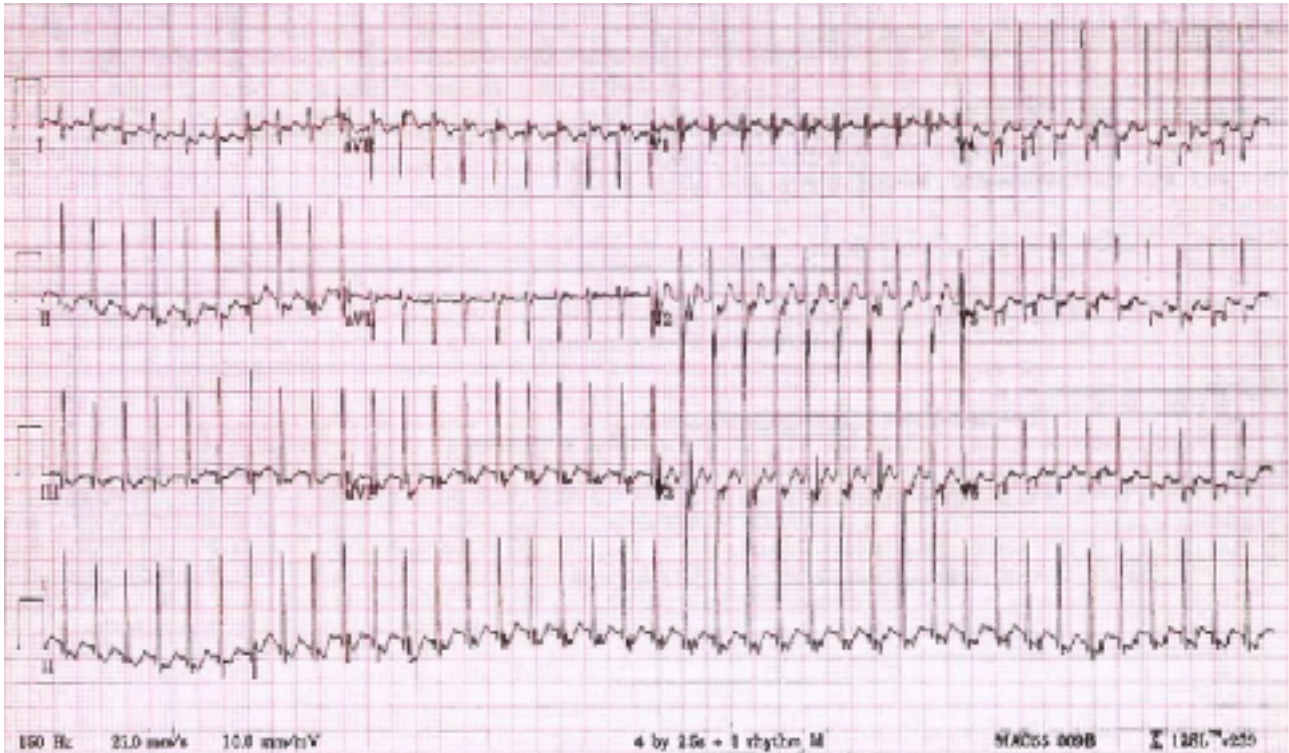


Investigation of the week

A previously well 6 month old male is brought to the Emergency with concerns of poor feeding about 2 hours before presentation.

On examination, he looks pale but has normal capillary refill time.

ECG taken:



1. What is your most likely diagnosis
2. You have a medical student with you who has several questions, including:
 1. What is the definition of this arrhythmia?
 2. Explain the pathophysiological mechanism
 3. Are there different forms of this arrhythmia? If so, which do infants predominantly have?
3. Complete the table below, giving 4 different treatment options

Treatment options	Mechanism of action	Dose (where applicable)