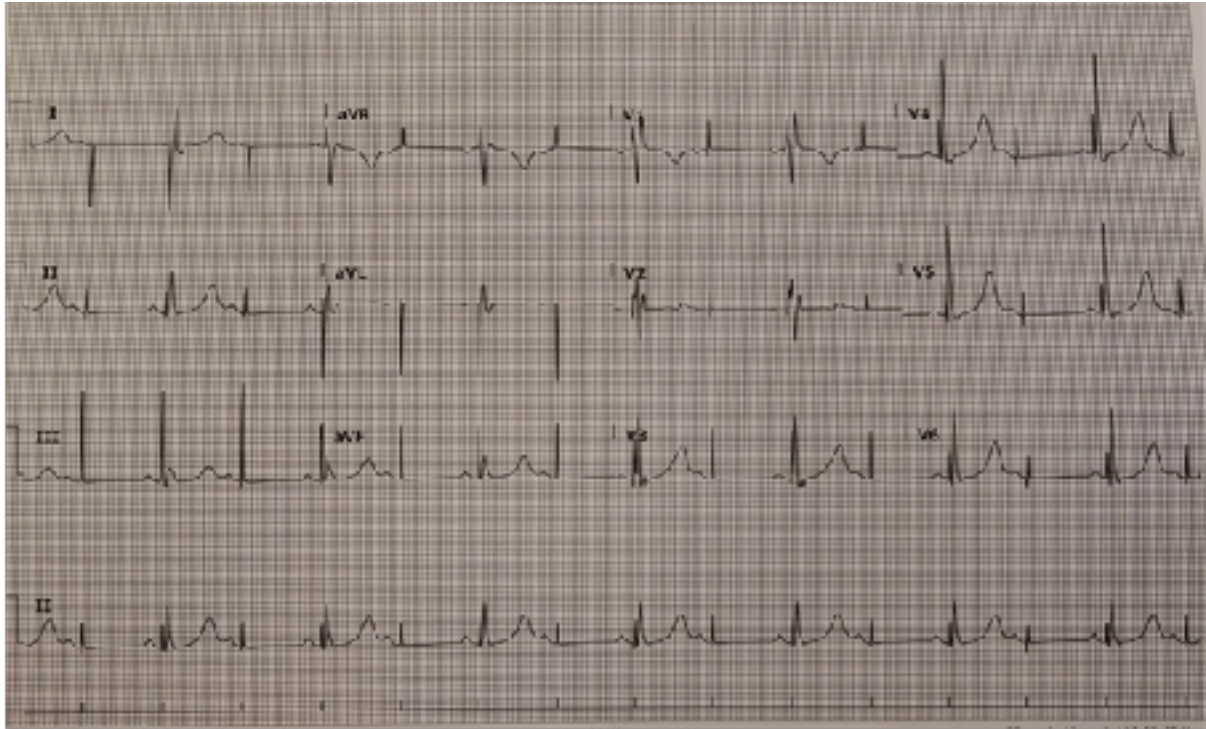


TSH ED Investigation of the Week Wednesday 31st January 2018

ECG:

An 80 year old man who was discharged yesterday following a pacemaker insertion has presented to ED following a syncopal episode.

His ECG is shown below:



Describe the ECG rhythm shown above:

.....
.....
.....
.....
.....
.....
.....
.....
.....
.....

(5 Marks)

What features of the QRS morphology assist you in diagnosis of the cause of the patient's syncope?

.....
.....
.....
.....

(2 Marks)

List 3 possible causes for this, 2 mechanical and 1 medical.

.....
.....
.....
.....
.....
.....

(3 Marks)