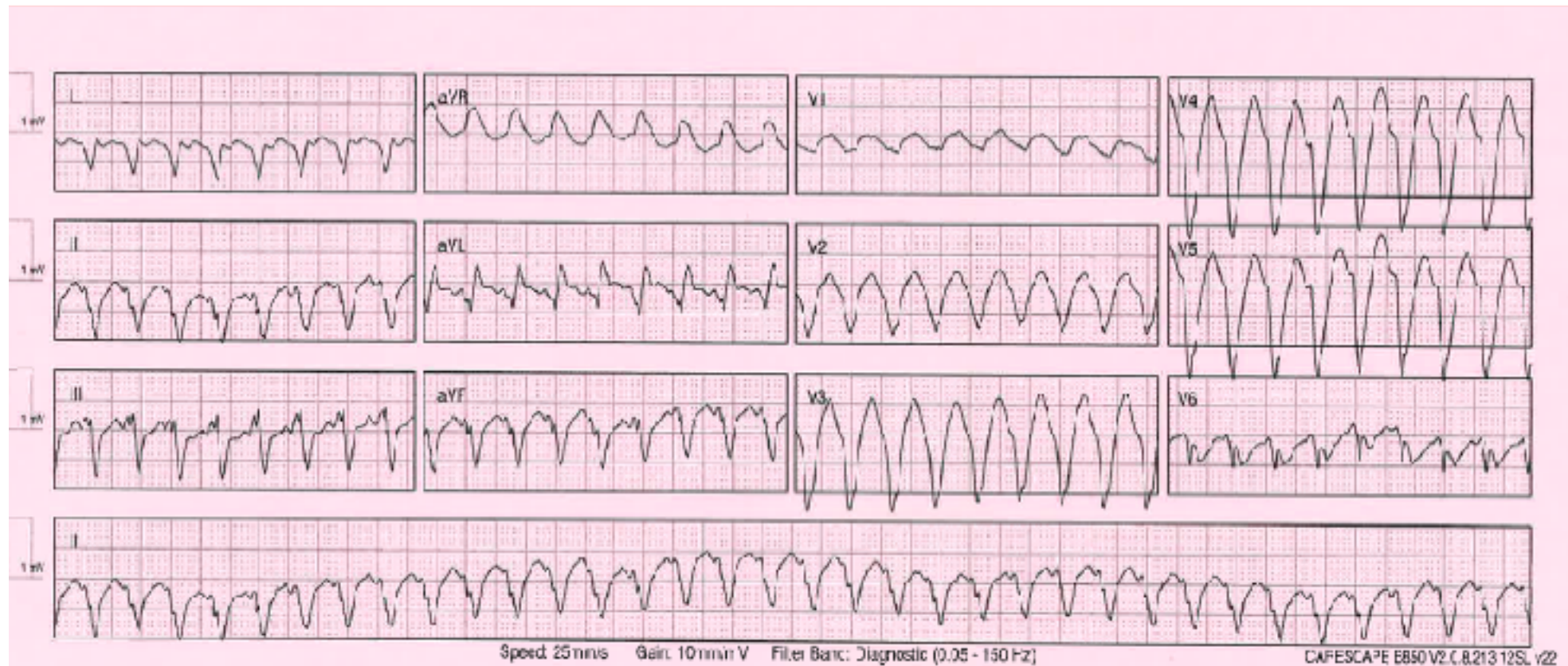


IMAGE OF THE WEEK JULY 25

An 80 yo man presents with sudden onset of dyspnoea and palpitations

This is his ECG



- List 3 key abnormalities on the ECG
- List 3 differential diagnoses for this rhythm
- List 3 features on history that will help distinguish between these diagnoses
- List 3 features on examination that will help distinguish between these diagnoses
- List 3 features that you would look for on the ECG that will help distinguish between these diagnoses

- Outline 3 treatment options for this dysrhythmia