

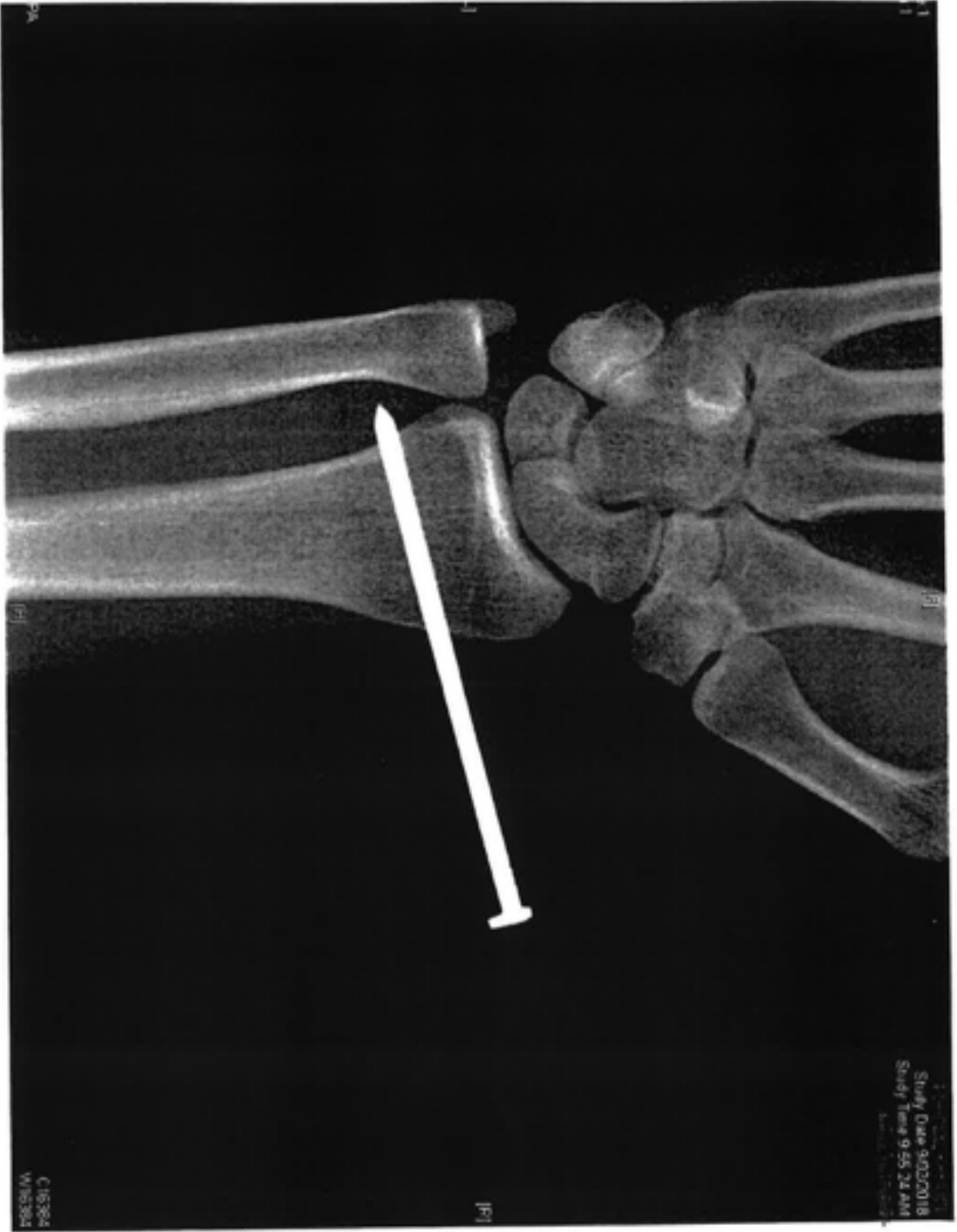
Investigation of the week: Wednesday 21 Feb

Below is the X-ray of a teenage apprentice carpenter who accidentally shot a nail into his left wrist.

He complained of pain and the left hand being cold, pale, dusky with an area of reduced sensation.

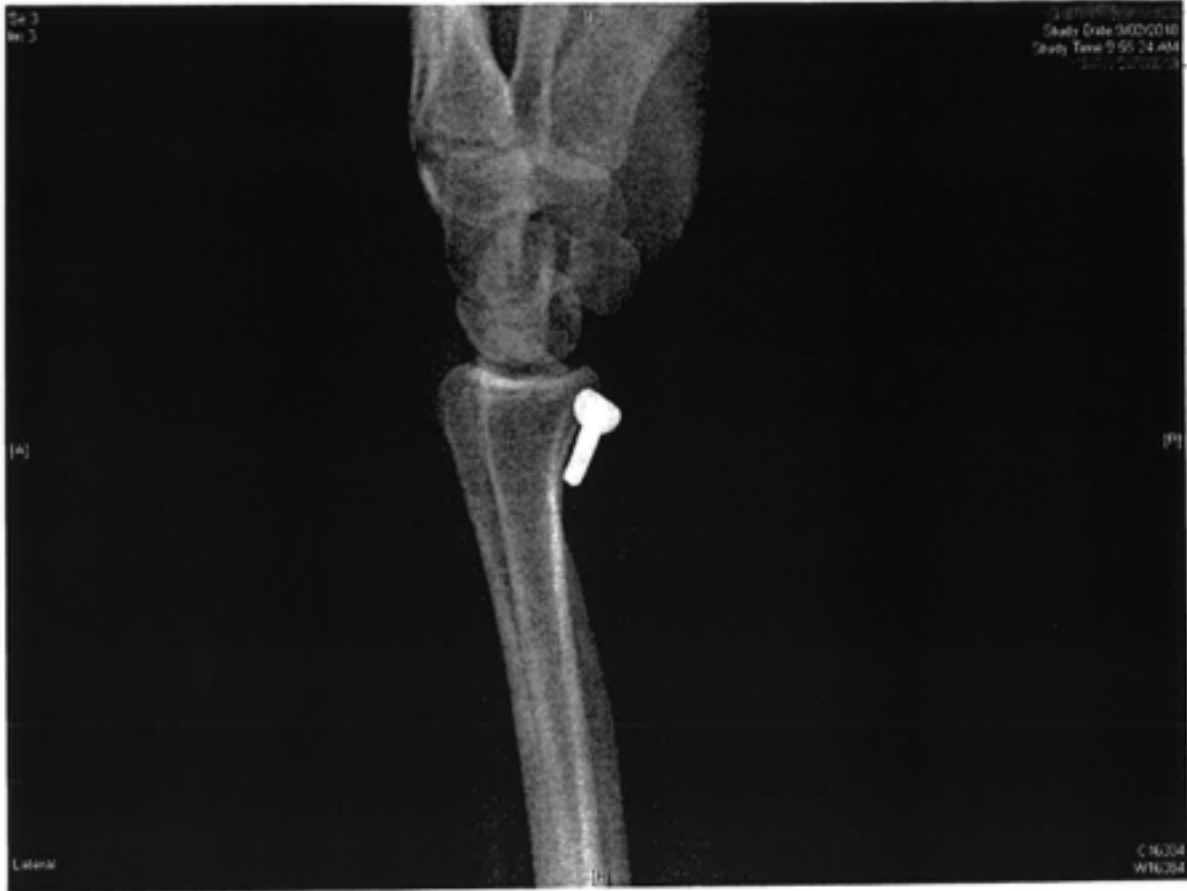There was minimal external haemorrhage.

1. What structures could potentially be damaged?
2. How would you assess and manage this patient?



Se 3
No 3

Study Date: 04/02/2010
Study Time: 9:55:24 AM
04/02/2010



Lateral

C:16204
W:16204