

Investigation of the week

Luis Winoto

51M with shoulder pain post fall

- fall from hoverboard backward
- impact to right scapula
- no other injuries
- no HI or LOC
- well otherwise
- RHD
- Last meal 3PM

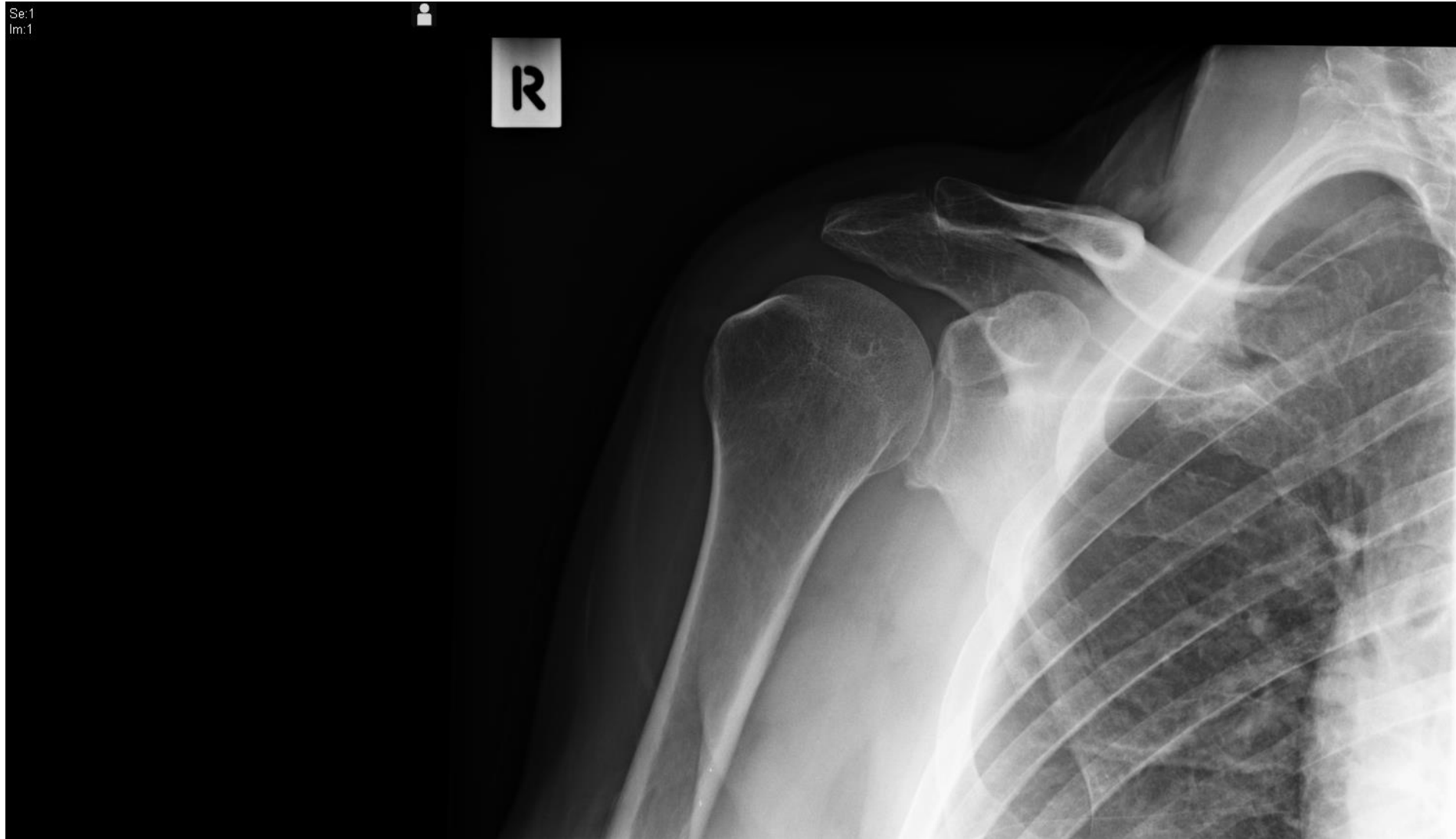
Examination

- comfortable
- closed injury
- swelling to right side of neck and over sternoclavicular joint
- tender on palpation to medial clavicle and scapular body
- tolerates gentle shoulder ROM
- neurovascularly intact
 - median, ulnar, radial and axillary n. motor and sensory intact
 - cap refill <2s, fingers pink and warm, radial & ulnar a. ++

Se:1
Im:1

R

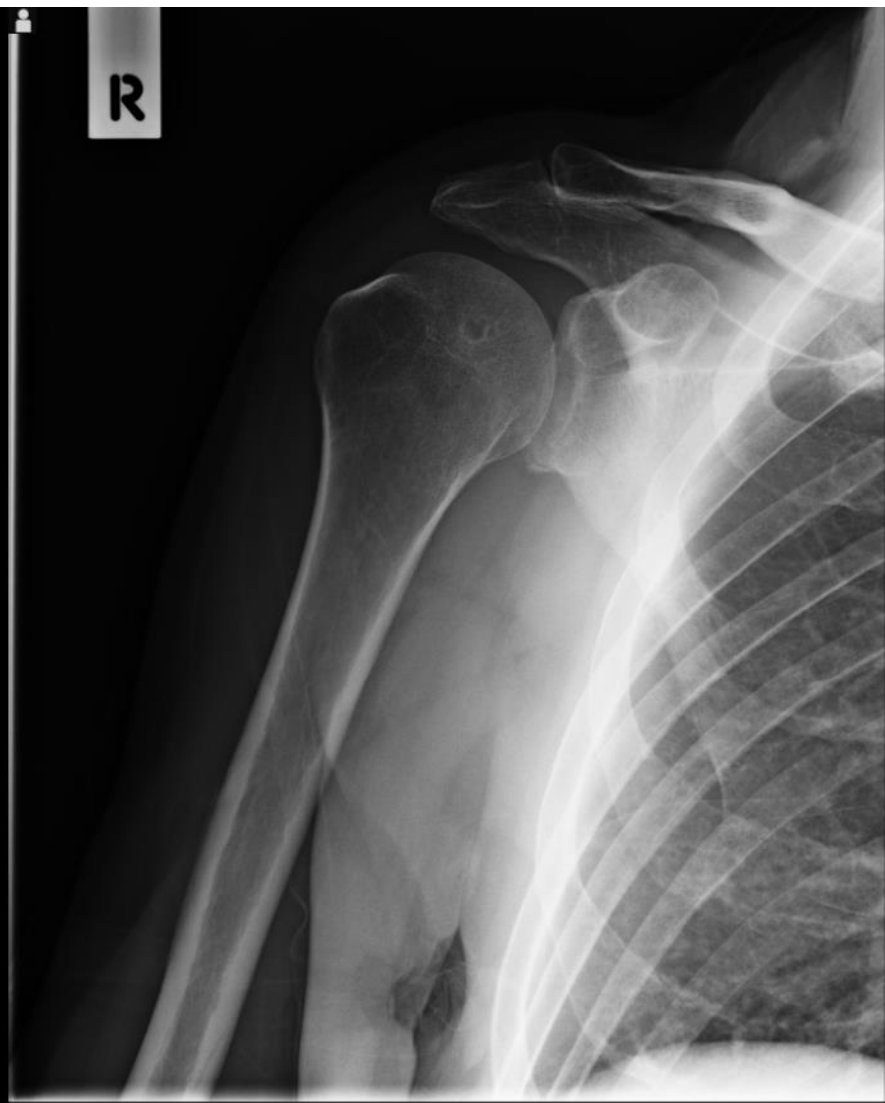Study Date: 25/12/2017
Image Time: 4:06:35 PM
MRN: 3415229



C2047
W4096

Se:1
Im:2

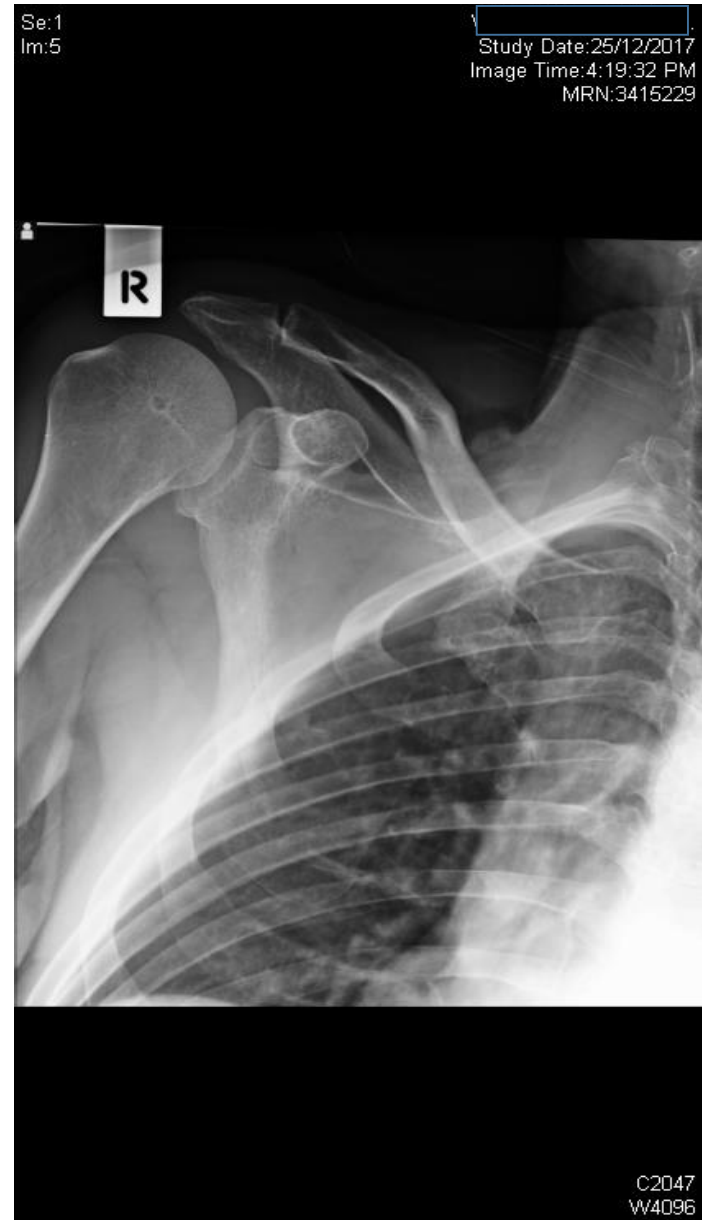R



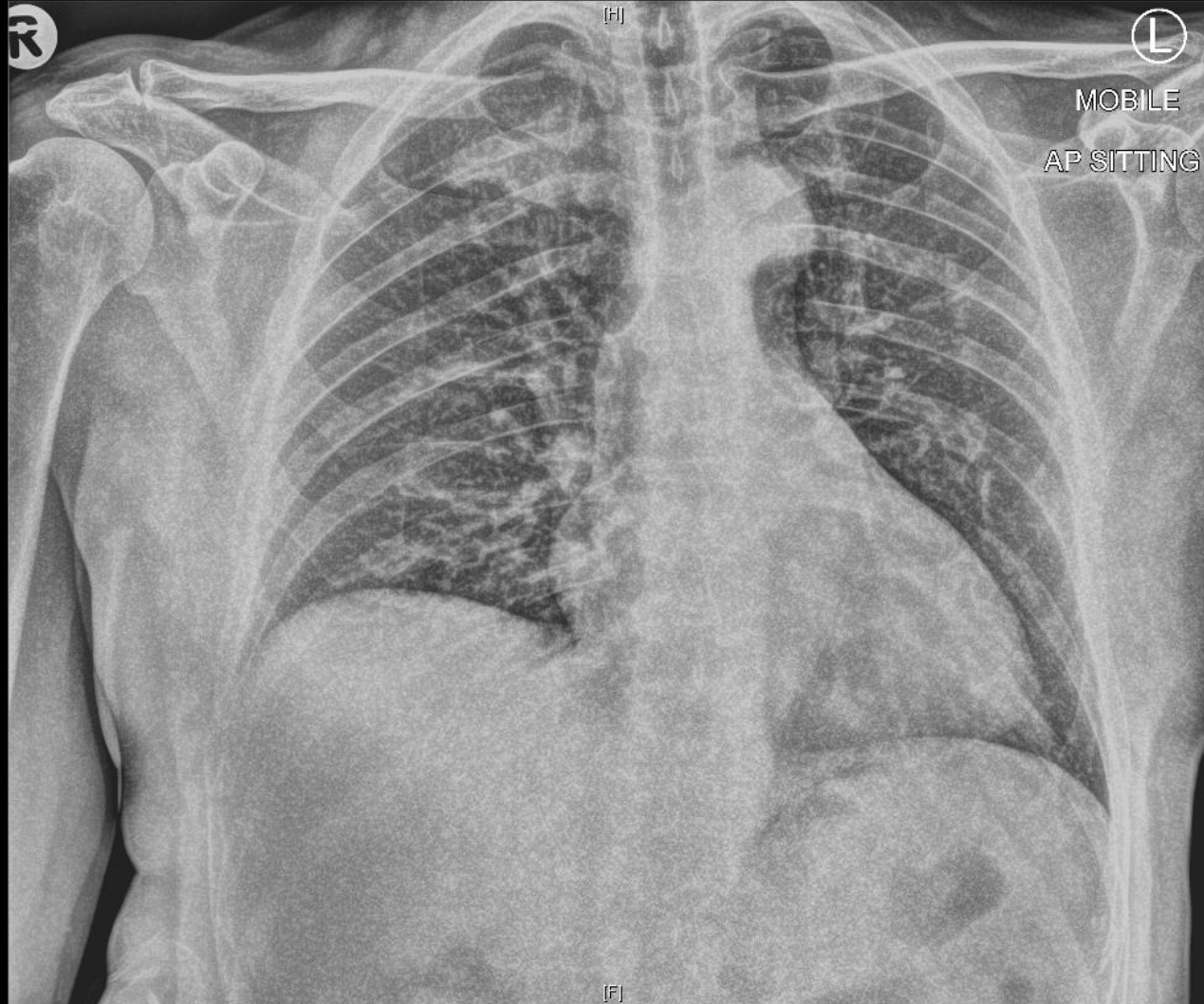Study Date: 25/12/2017
Image Time: 4:10:57 PM
MRN: 3415229

C2047
W4096

Any abnormalities in this image?



Se:6
Im:6



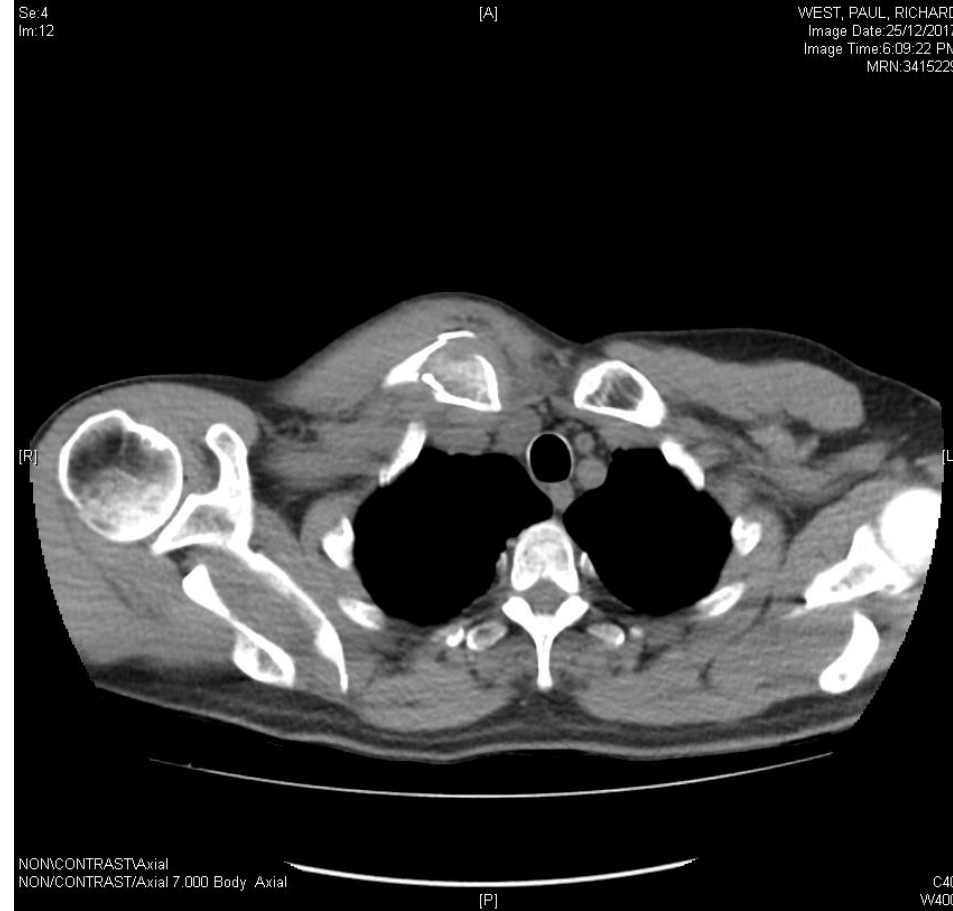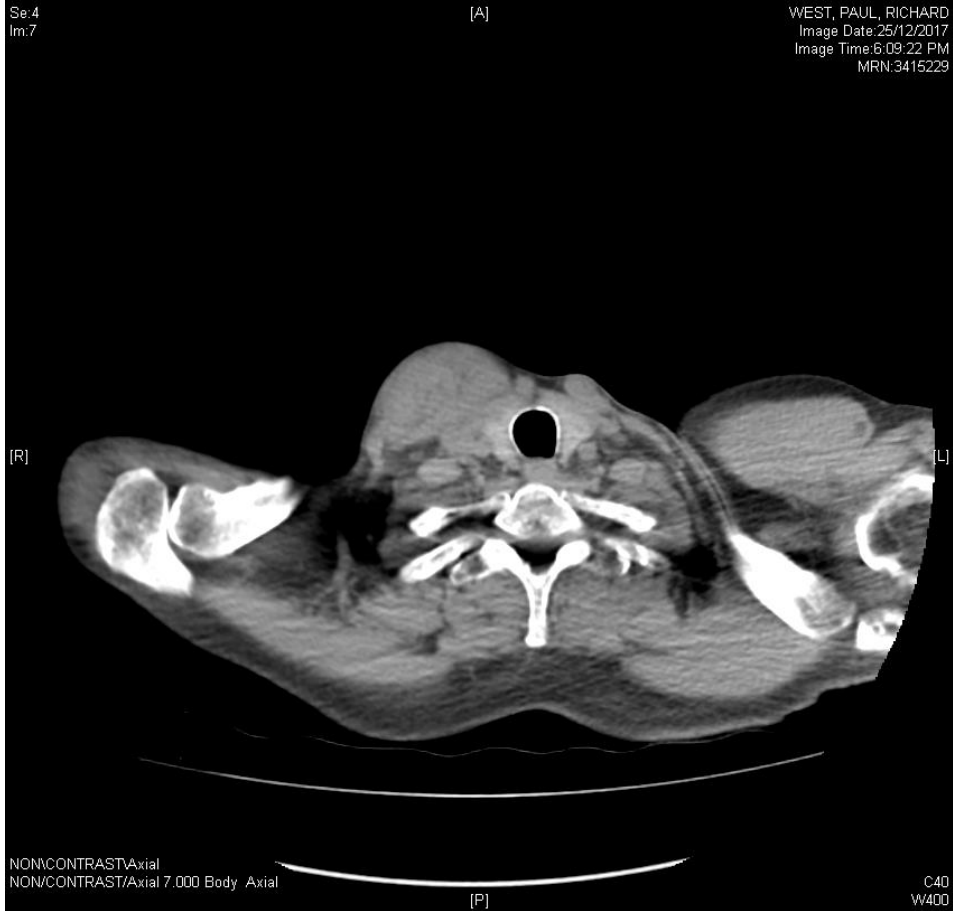Study Date: 25/12/2017
Image Time: 6:03:21 PM
MRN: 3415229

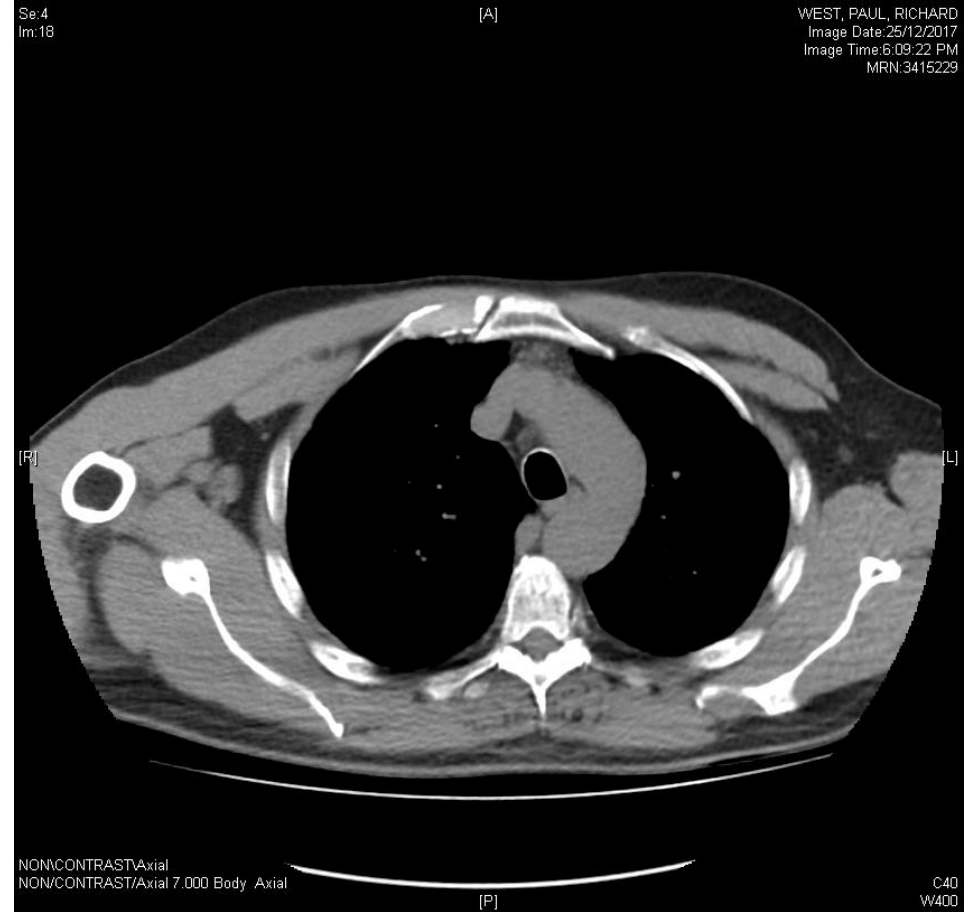
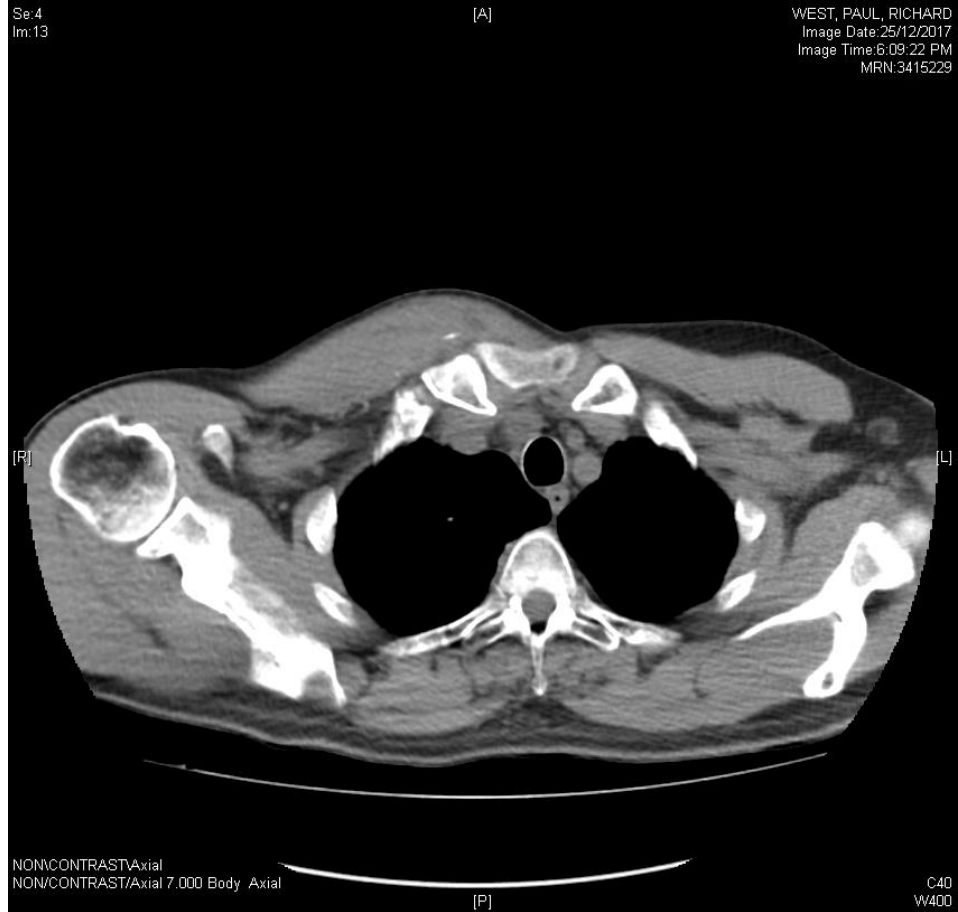AP

C16384
W16384

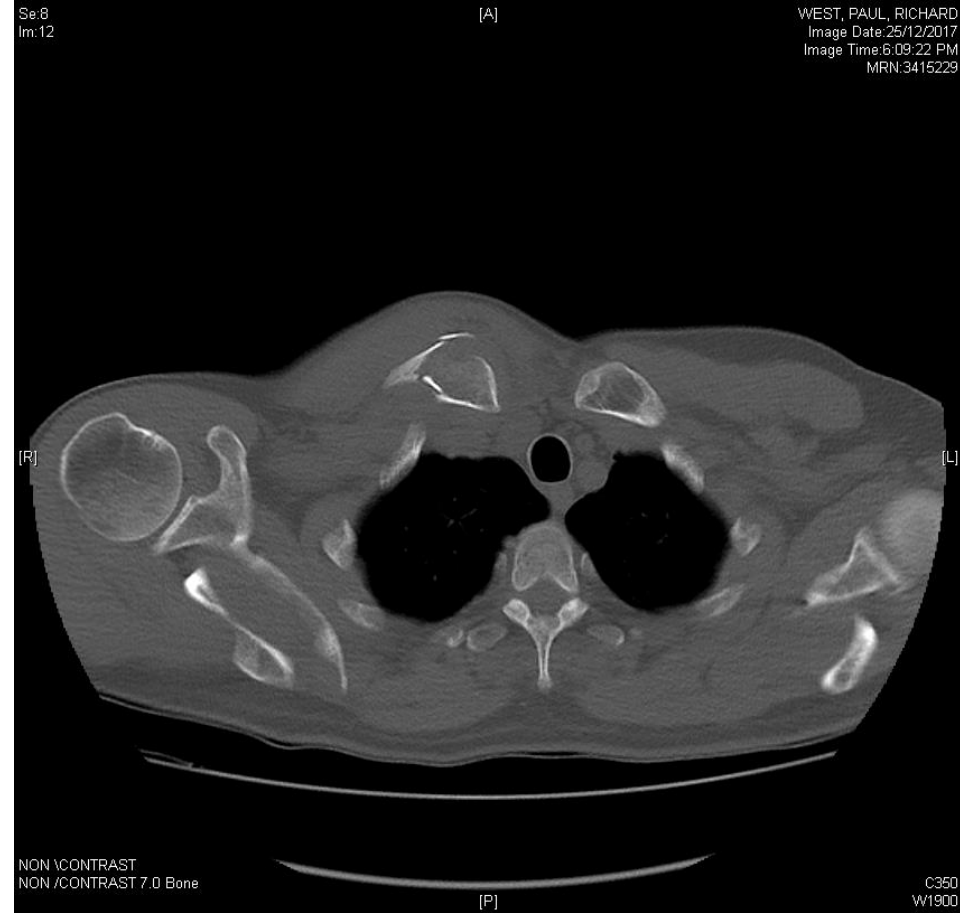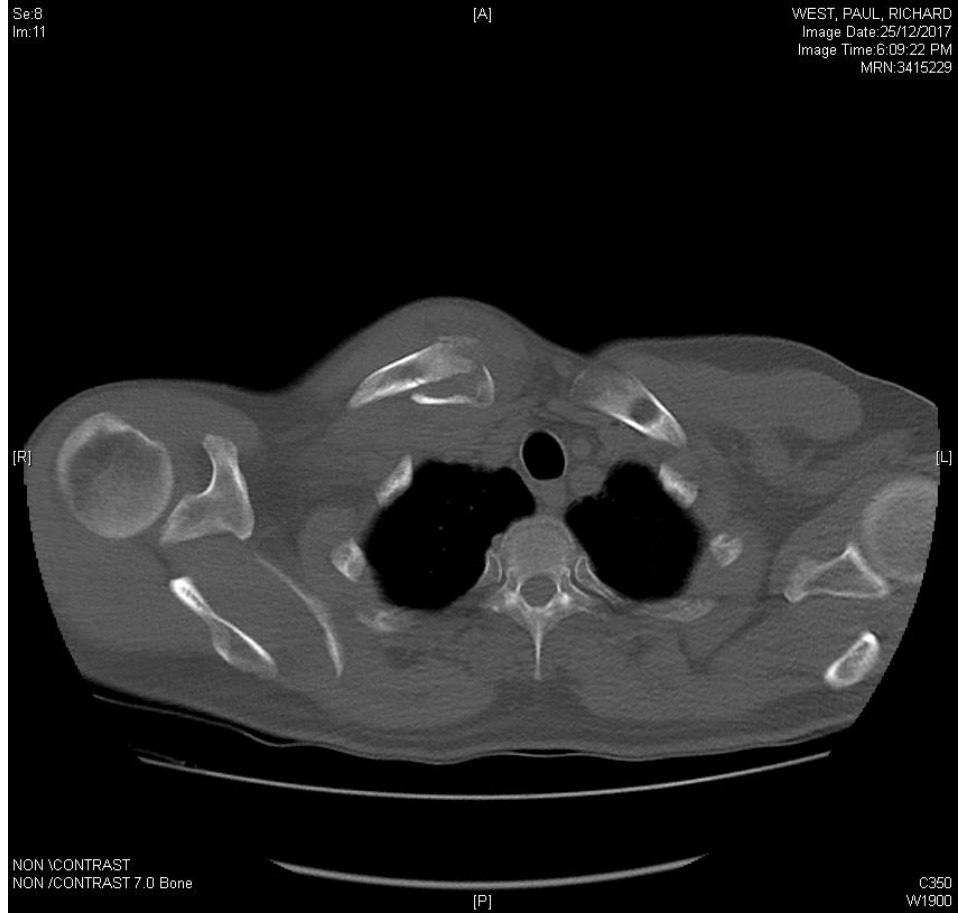Describe and interpret Xrays

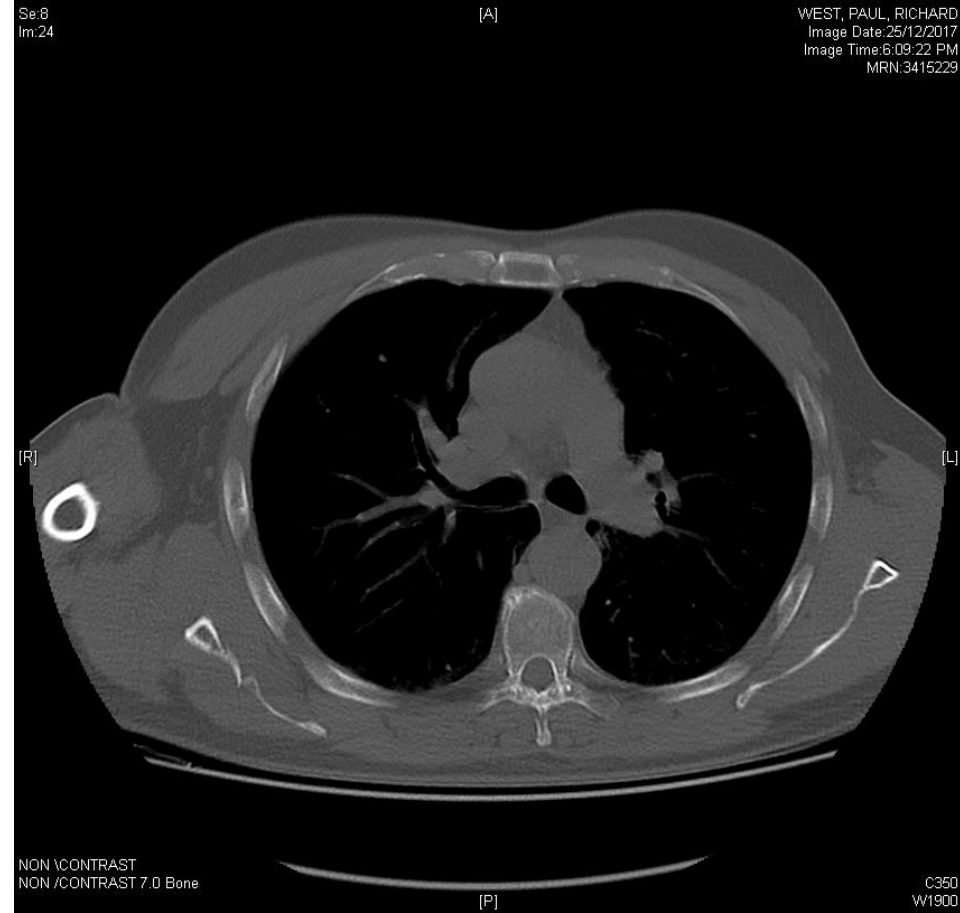
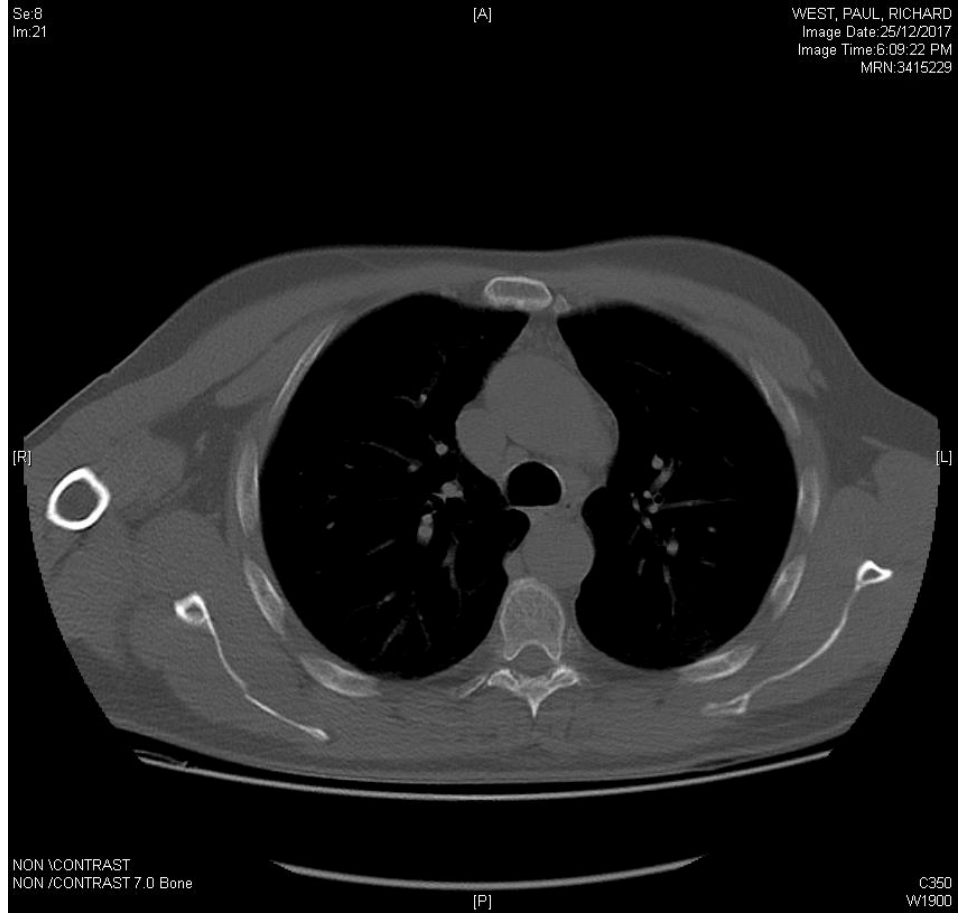
Further investigations?





Describe and interpret sequential soft tissue CT series





Describe and interpret sequential bone windows

What is your management?