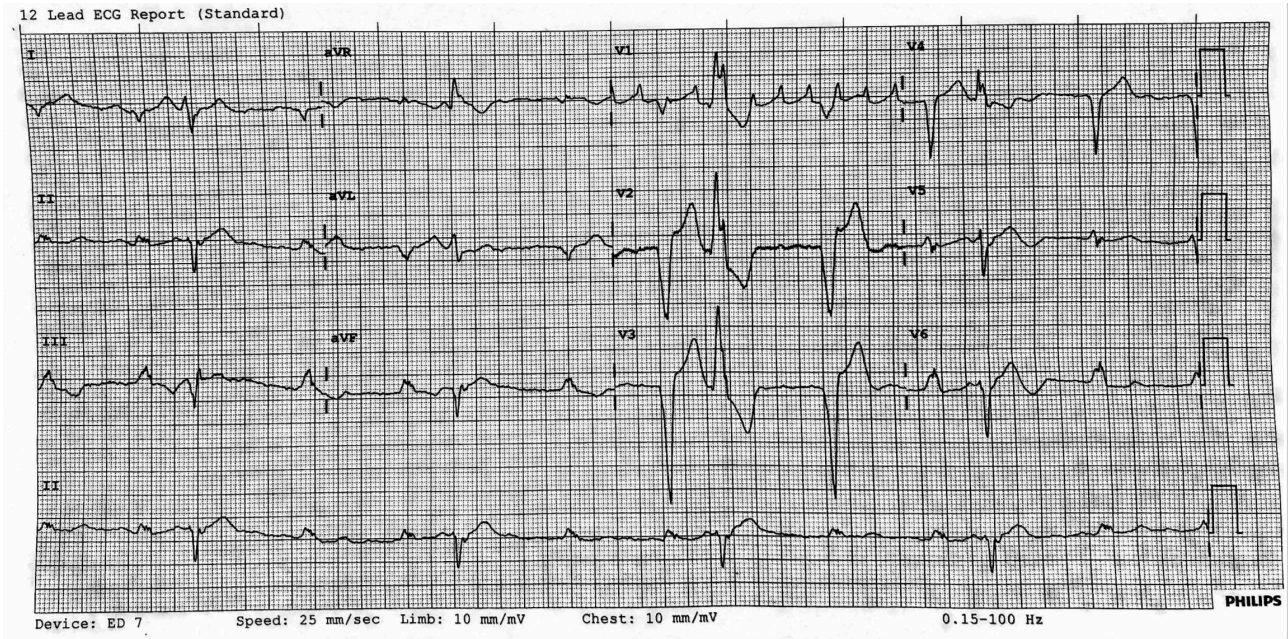


76yo man with IHD, htn PPM for AF with new onset palpitations and no other associated symptoms.

BP 140/77

Sats 98%



1. Describe and interpret ECG

2. Describe your ED mgt.