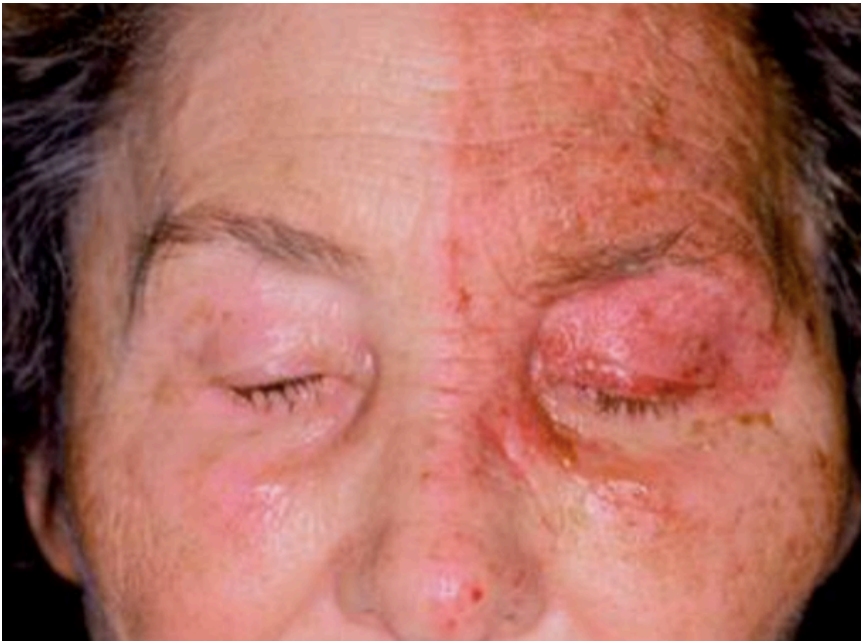

A 72 year old female presents with a 3 day history of a painful rash to her face as pictured below.

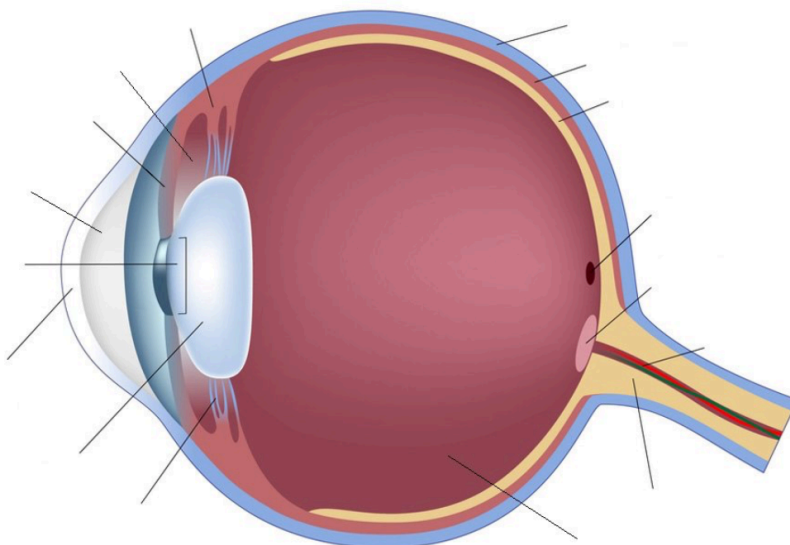
PMH: HT



1. What is the most likely diagnosis?

2. Briefly describe the pathology of the condition. Outline the anatomical pathway of the involved nerve

3. Label the image below



4. What features on history would you specifically seek?

4. What is Hutchinson sign and why is it important?

5. What is your treatment plan?

6. List 4 complications.